

Dental findings in wild great apes from macerated skull analysis

Anja Albrecht¹ | Verena Behringer²  | Oliver Zierau³ | Christian Hannig¹ 

¹Policlinic of Operative Dentistry, Periodontology, and Pediatric Dentistry Dresden, Faculty of Medicine 'Carl Gustav Carus', Technische Universität Dresden, Dresden, Germany

²Endocrinology Laboratory, German Primate Center, Leibniz Institute for Primate Research, Göttingen, Germany

³Environmental Monitoring & Endocrinology, Faculty of Biology, Technische Universität Dresden, Dresden, Germany

Correspondence

Christian Hannig, Policlinic of Operative Dentistry, Periodontology, and Pediatric Dentistry Dresden, Faculty of Medicine 'Carl Gustav Carus', Technische Universität Dresden, Fetscherstraße 74, 01307, Dresden, Germany.

Email: Christian.Hannig@ukdd.de

Abstract

Oral health is a crucial aspect of overall well-being in both humans and nonhuman primates. Understanding the oral pathologies and dental conditions in apes can provide valuable insights into their evolutionary history, dietary habits, and overall health. The present study evaluates dental findings in wild great apes from museum specimens to gain insights into the influence of natural nutrition on dental health. Complete macerated skulls of wild, adult great apes from the collection of the Museum of Natural History, Berlin, Germany, were examined. We analyzed skulls of 53 gorillas (*Gorilla gorilla*), 63 chimpanzees (*Pan troglodytes*), and 41 orangutans (*Pongo* spp.). For each skull, we recorded wear of dental hard tissues (Lussi and Ganss index), carious lesions, and periodontal bone loss. Incisal and occlusal dental hard tissue defects were found in all skulls, as well as considerable external staining. In all species, incisors and canines showed the greatest loss of tissue, followed by molars. The wear of molars decreased from the first to the third molars, premolars showed the least pronounced defects. Some individuals had apical osteolytic defects along with severe dental hard tissue loss with pulp involvement or after dental trauma, respectively ($n = 5$). Our study did not observe any carious lesions among the examined great ape skulls. However, we did find evidence for localized or generalized periodontal bone loss in a subset of the specimens ($n = 3$ chimpanzees, $n = 7$ orangutans). The natural diet and foraging behavior of great apes induces abrasion and attrition of dental hard tissue but does not yield carious lesions. The occurrence of periodontitis in individual apes indicates that the natural circumstances can induce periodontal bone loss even in the wild, despite physiological nutrition.

KEYWORDS

caries, foraging behavior, oral diseases, periodontitis, polyphenols

Abbreviations: (I2-C1-P2-M3), number of incisors, canines, premolars, molars; ICDAS, International Caries Detection and Assessment System.

Anja Albrecht and Verena Behringer shared the first authorship.

Oliver Zierau and Christian Hannig shared senior authorship.

This is an open access article under the terms of the [Creative Commons Attribution](https://creativecommons.org/licenses/by/4.0/) License, which permits use, distribution and reproduction in any medium, provided the original work is properly cited.

© 2023 The Authors. *American Journal of Primatology* published by Wiley Periodicals LLC.

1 | INTRODUCTION

Research on oral health in nonhuman primates, particularly apes, has provided valuable insights into their dental pathologies, dietary adaptations, and evolutionary implications. As our closest living relatives, great apes (*Gorilla gorilla*, *Pongo* spp., *Pan troglodytes*, and *Pan paniscus*) (Kuhlwilm et al., 2016), offer a unique opportunity to explore the epidemiology of oral diseases from an evolutionary perspective (Cuozzo & Sauter, 2012; Kalluri, 2021; Phillips-Conroy et al., 1993). Despite variations in body size, social structure, and behavior, all great apes share a similar dental formula (number of incisors, canines, premolars, molars [I2-C1-P2-M3]) (Ankel-Simons, 2007).

Unlike humans, great apes exhibit pronounced canines, which are associated with sexual dimorphism, especially in gorillas and orangutans. Furthermore, great apes are primarily folivorous (Gerstner & Pruetz, 2022; Mackinnon, 1974; Uwimbabazi et al., 2019; Wrangham et al., 1991), but differ in their dietary preferences. For instance, gorillas depend on terrestrial herbaceous vegetation (THV) when fruits are scarce (Doran et al., 2002; Masi et al., 2009; Watts, 1984). Chimpanzees (*Pan troglodytes*) are primarily frugivorous, relying on ripe fruits and young leaves. Their diet is complemented with mammals, birds, eggs, and insects (McGrew, 1983; Stanford & Nkurunungi, 2003; Tweheyo et al., 2004; Wrangham et al., 1991). Orangutans (*Pongo* spp.), considered frugivores, supplement their diet mainly with seeds, unripe fruits, and bark when fruits are not available (Hamilton & Galdikas, 1994; Knott, 1998).

Overall, the diet of all wild-living great apes consists of coarse and unprocessed food, which has been linked to a more pronounced loss of dental hard tissue compared with modern humans, who primarily consume processed food items (Alt et al., 2022; Woelber et al., 2016). In modern human societies, noncarious dental hard tissue loss is mainly caused by pathological conditions like bruxism or exposure to intrinsic (gastric juice) or extrinsic (e.g., acidic beverages) acids (Hannig & Hannig, 2014). By contrast, in great apes, dental attrition and abrasion is a physiological consequence of mastication (Welsch, 1967). It is rare to find an unworn occlusal or incisal surface in both prehistoric humans and recent great apes (Alt et al., 2022; Molnar & Molnar, 1985; Münster et al., 2018; Welsch, 1967).

Throughout human history, changes in dietary habits, such as consumption of softer foods and the use of tools to manipulate food, have resulted in alterations in the pattern of dental wear, also leading to a reduction in tooth size (Alt et al., 2022; Kaidonis, 2008). Not only have humans changed the way they eat and prepare food, but there has also been a dramatic shift in the types of food items consumed. Dietary changes during the transition to settled societies, the advent of agriculture, and ultimately industrialization, including the consumption of sugar, have contributed to a higher prevalence of carious lesions in modern humans compared with abrasions and attritions observed in prehistoric humans and great apes (Alt et al., 2022; Crovella & Ardito, 1994; Elgart, 2010; Towle et al., 2017).

Numerous studies have documented common oral pathologies in apes, including calculus, periodontal diseases, dental attrition, tooth

loss, osteopenia, and caries (Crovella & Ardito, 1994; Dean et al., 1992; Elgart, 2010). Dental wear and periodontitis are common conditions observed in both captive and wild-living apes, reflecting the challenges associated with their diet and the aging process (Gonzalez et al., 2016; Lowenstine et al., 2016; Pandruvada et al., 2016; Phillips-Conroy et al., 1993). Beyond age-dependency, periodontitis in apes shows substantial variability in disease manifestation. While some individuals are susceptible to periodontitis, others appeared to demonstrate resistance to more severe disease, even as they age (Phillips-Conroy et al., 1993). This observation is in line with the similar findings in human daily dental routine. However, instances of caries and apical osteolytic phenomena remain relatively infrequent among wild-living nonhuman primates, including great apes (Crovella & Ardito, 1994; Schultz, 1935). Research comparing different ape species has revealed variations in dental diseases, wear patterns, and enamel thickness. For example, African apes, such as mountain- and lowland gorillas as well as bonobos exhibit more dental diseases than Grauer's gorillas or eastern chimpanzees (Elgart, 2010). These variations may be attributed to dietary differences, including the consumption of abrasive or tough foods, as well as differences in enamel thickness among species (Aiello et al., 1991; Elgart, 2010).

Apart from periodontal diseases and dental attrition, other dental pathologies have been identified in apes. These include odontogenic abscesses, enamel hypoplasia, fractures, and developmental defects (Kakehashi et al., 1963; Legge, 2012; Scheels, 2023; Stoner, 1995). The presence of odontogenic abscesses in bonobos and chimpanzees indicates the occurrence of severe dental infections as a result of dental trauma or severe periodontitis (Kalluri, 2021; Lukacs, 1999).

Studies on dental pathologies and wear patterns in apes contribute to our understanding of primate ecology, behavior, and evolutionary history. Dental morphology and microwear analysis offer valuable information on diet and feeding behaviors, which can be extrapolated to extinct hominins and their ecological niches (Cuozzo & Sauter, 2012; Gordon, 1982). Furthermore, comparisons between ape species and humans can provide insights into the evolution of oral diseases and their epidemiology (Kalluri, 2021).

Our study investigated the effects of natural diets and respectively living conditions on tooth structure defects in several great ape species (gorilla, chimpanzee, and orangutan) using skulls of individuals obtained from the wild at the Berlin Museum of Natural History, Germany. We expected (1) a low prevalence of caries, given their natural dietary habits and living conditions but considerable dental wear in nearly all individuals, and (2) periodontal bone loss in some apes.

2 | METHODS

2.1 | Subjects

Our project involved the examination of 157 complete adult individual skulls, of unknown ages and both sexes represented.

These samples included 53 gorillas (*Gorilla gorilla*), 63 chimpanzees (*Pan troglodytes*), and 41 orangutans (*Pongo spp.*). The macerated skulls were obtained from the collections of the Museum of Natural History, Berlin, Germany, and had been collected during the colonial era before 1914. Specifically, gorillas and chimpanzees were gained from Cameroon, Gabon, and the Congo area, former German, French, and Belgium colonies, respectively. The included orangutan specimens were obtained from the islands Borneo and Sumatra.

For our analysis, we excluded single skulls of juvenile or zoo-housed apes in the quantification of hard tissue defects, but their skulls were considered for photographic documentation if they yielded interesting or typical findings. The skulls were photographed in a standardized manner from various perspectives, with a focus on capturing detailed images of the teeth. During our examination, we assessed potential carious lesions, dental hard tissue loss, periodontal bone loss, and tooth loss for various pathologies in the collected specimens.

2.2 | Documentation and dental examination

The evaluation process was conducted using photographs of the individual skulls, captured with a Canon-brand SLR camera model EOS 6D Mark II and an 18–55 mm lens with a focal length and f-number of 1: 3.5–5.6. A MACRO 0.25/0.8 ft focusing distance was maintained constantly at a distance of 25 cm. The skulls were photographed against a black background under daylight conditions.

The photo evaluation was carried out at the University Hospital, Polyclinic of Operative Dentistry, Periodontology, and Pediatric Dentistry Dresden, Germany. The examination scheme recorded existing teeth, potential carious lesions, degrees of abrasion, and periodontal bone loss. Potential carious lesions were examined according to the ICDAS classification common in dental research (Ormond et al., 2010).

The degree of occlusal/incisal hard tissue defects was classified into four different grades of abrasion according to LUSI and GANSS scheme: grade 0—no loss of dental hard tissue, 1 for enamel loss; grade 2 for dentin exposure of less than 1/3 of the occlusal surface; grade 3 for dentin exposure of more than 1/3 of occlusal surface; grade 4 for pulp exposure (Lussi & Ganss, 2014). During the evaluation of the photographs, a clear differentiation between teeth with completely intact enamel and those showing initial enamel loss was not feasible. Given the rarity of fully intact enamel in wild animals, we decided to combine grade 0 and grade 1 classifications.

The degree of abrasion was determined for each individual tooth, and the teeth with the same degrees of abrasion were summed up, the percentage of all examined teeth with incisal/occlusal hard tissue loss with dentine exposure was calculated (Table 1).

The loss of dental hard tissue in different tooth groups was calculated separately for the maxilla, and the mandibula (maxillary and mandibular molars, premolars, canines, incisors, incisors, respectively); in the following the percentage of teeth from a specific subgroup affected by a certain grade of abrasion was calculated.

The distribution of abrasions in different degrees of abrasion was determined. Missing teeth and potential carious lesions were marked, and bone loss was evaluated considering localized (affecting only single teeth) as well as generalized bone loss (affecting more than 30% of the roots) and furcation involvement of teeth. The bone loss was evaluated for each skull and not for each individual tooth (probing of the pockets was not possible).

The examining dentists were able to clearly discern teeth that had been lost postmortem; only teeth lost antemortem with evident bony healing were included in the count.

3 | RESULTS

3.1 | General observations

All macerated skulls of wild animals showed considerable tooth staining, even among young individuals undergoing the eruption of permanent teeth (which were excluded from quantitative evaluation). Furthermore, pronounced occlusal and incisal surface wear was evident, potentially indicative of age-related factors. Examples of this wear are shown in Figures 1–3, and the proportion of hard tissue loss with dentine exposure is provided in Tables 1 and 2, categorized by the tooth types. Specific additional findings are listed in Table 3, and selected cases are illustrated in Figures 4 and 5.

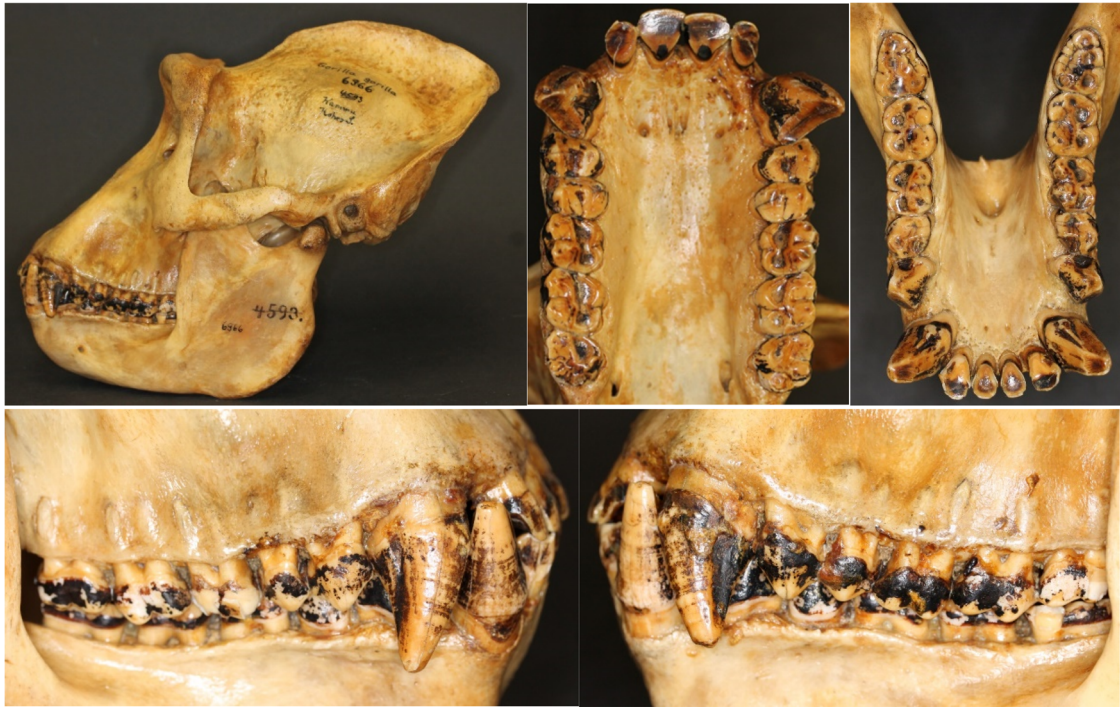In certain individual gorillas and orangutans, wear had progressed to the extent of reaching the former pulp chamber. However, in most cases, the deposition of tertiary dentin had prevented pulp exposure. Individuals where root canals were exposed to the oral cavity were associated with apical osteolysis (Figure 5, acute or chronic inflammatory lesion around the apex of a tooth root).

This study did not find any carious lesions in any of the great apes investigated.

TABLE 1 Distribution of abrasion levels according to Lussi and Ganss (2014) in adult gorillas, chimpanzees, and orangutans, percentage of affected teeth.

Species	Percentage of all examined teeth with abrasion grade			
	Grade 0-1	Grade 2	Grade 3	Grade 4
gorillas: <i>n</i> = 53 skulls, 1600 teeth	44%	41%	13%	2%
chimpanzees: <i>n</i> = 63 skulls, 1739 teeth	30%	60%	9%	1%
orangutans: <i>n</i> = 41 skulls, 1203 teeth	42%	46%	10%	2%

Gorilla gorilla – 6966 – Cameroon, Africa ♂



Gorilla gorilla – 7157 – Samakita, Ogowe/Gabon, Africa ♂

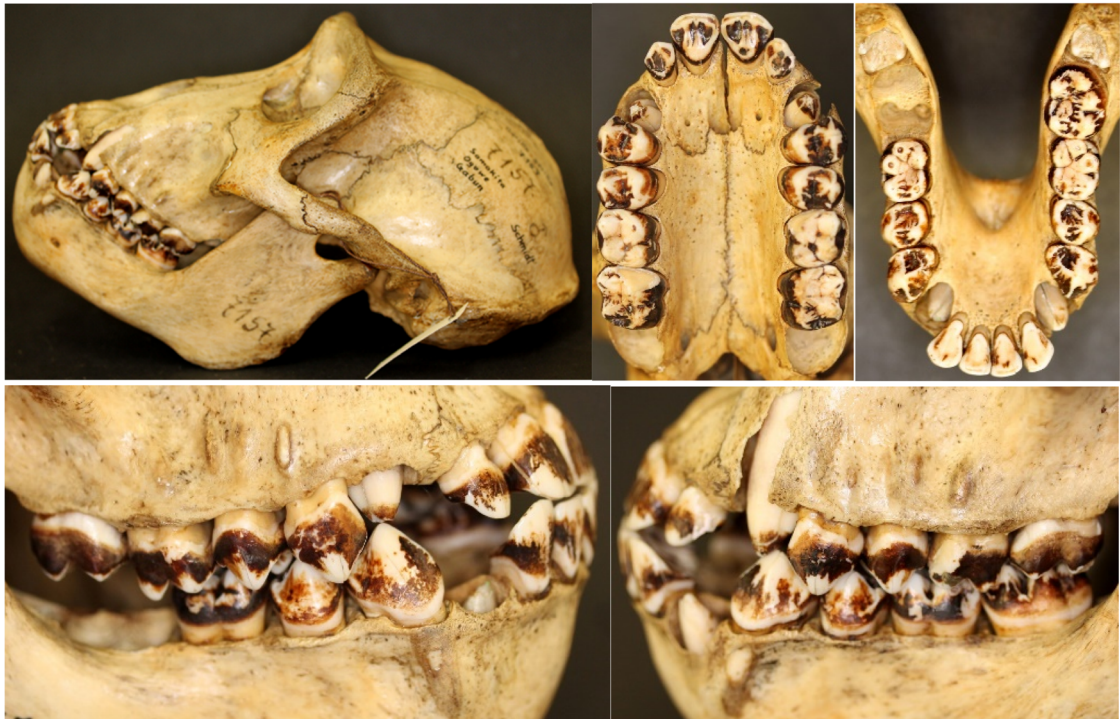

FIGURE 1 Male *Gorilla gorilla*, typical appearance of adults' dentition: pronounced staining and abrasions but no signs of caries or periodontal bone loss. In individual 7157, not all teeth are fully erupted but even in this juvenile stadium extensive discolorations and abrasions are evident. Missing 18, 28, and 47 were lost *postmortem*.

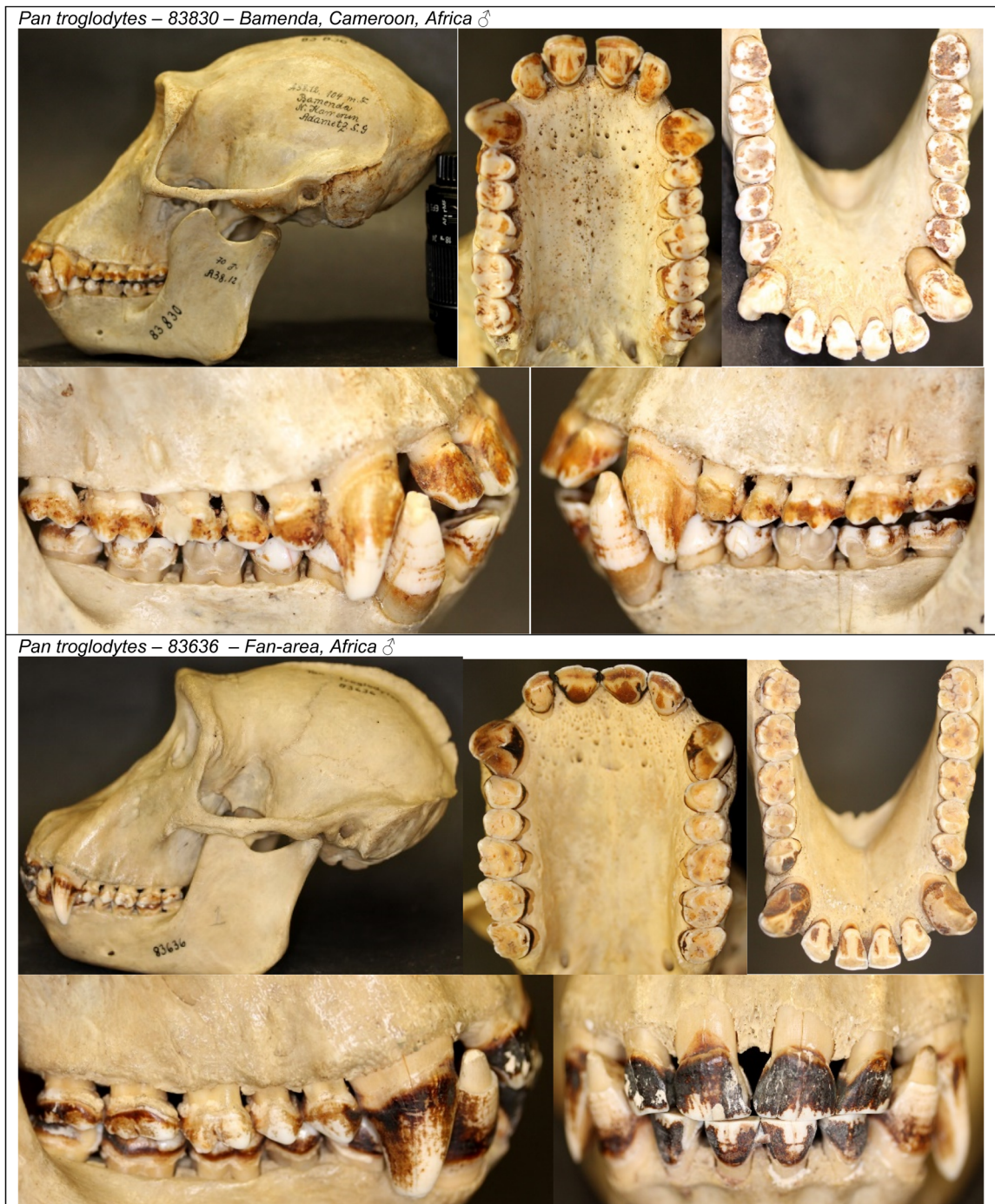

FIGURE 2 Male *Pan troglodytes*, chimpanzee; typical appearance of adults' dentition: pronounced staining and abrasions but no signs of caries or periodontal bone loss.

3.2 | Wear, species-specific details

3.2.1 | *Gorilla gorilla*

Moderate wear was the prevailing finding among all teeth, with the majority of cases not exceeding grade 3 (Figure 1, Table 1). The maxillary canines exhibited the highest degree of wear, followed by the maxillary incisors, and subsequently the mandibular canines and

molars (Table 2). In premolars, the least amount of wear across both maxilla and mandibula was found.

Upon classification of the degree of wear according to the LUSI and GANSS scheme, it was shown that approximately 56% of the teeth had hard tissue defects of grade 2 or higher. Nevertheless, initial enamel defects without dentin involvement (graded as either 0/1) were also detected in 44% of all analyzed teeth. Notably, pulp exposure-associated tooth damage was only observed in 2% of the examined teeth.

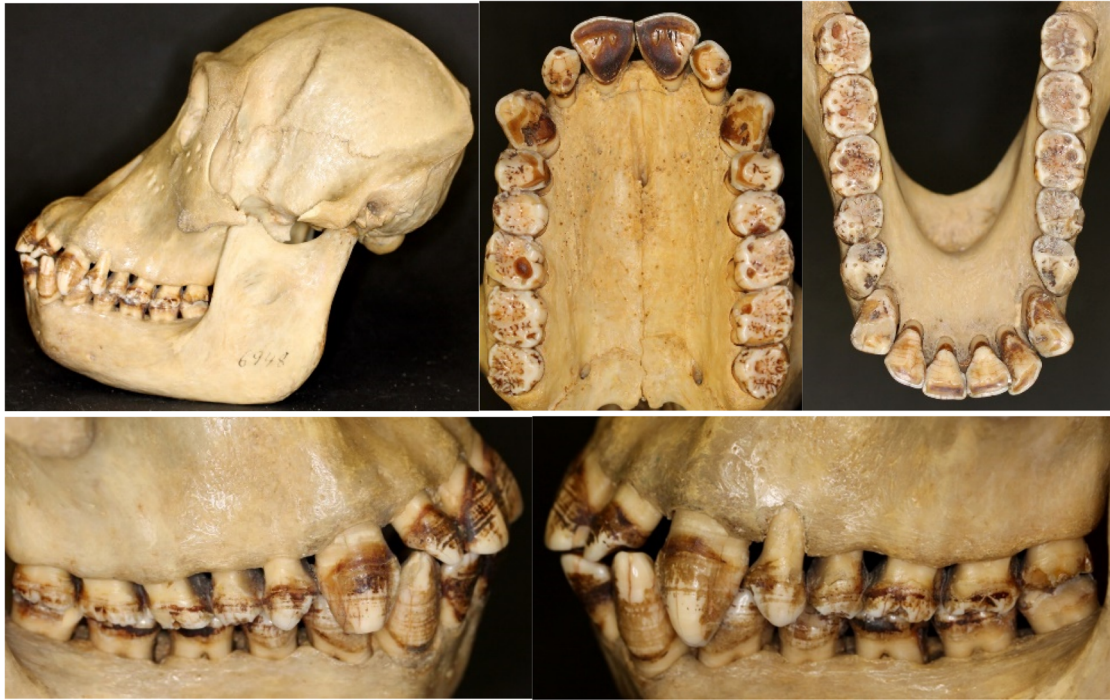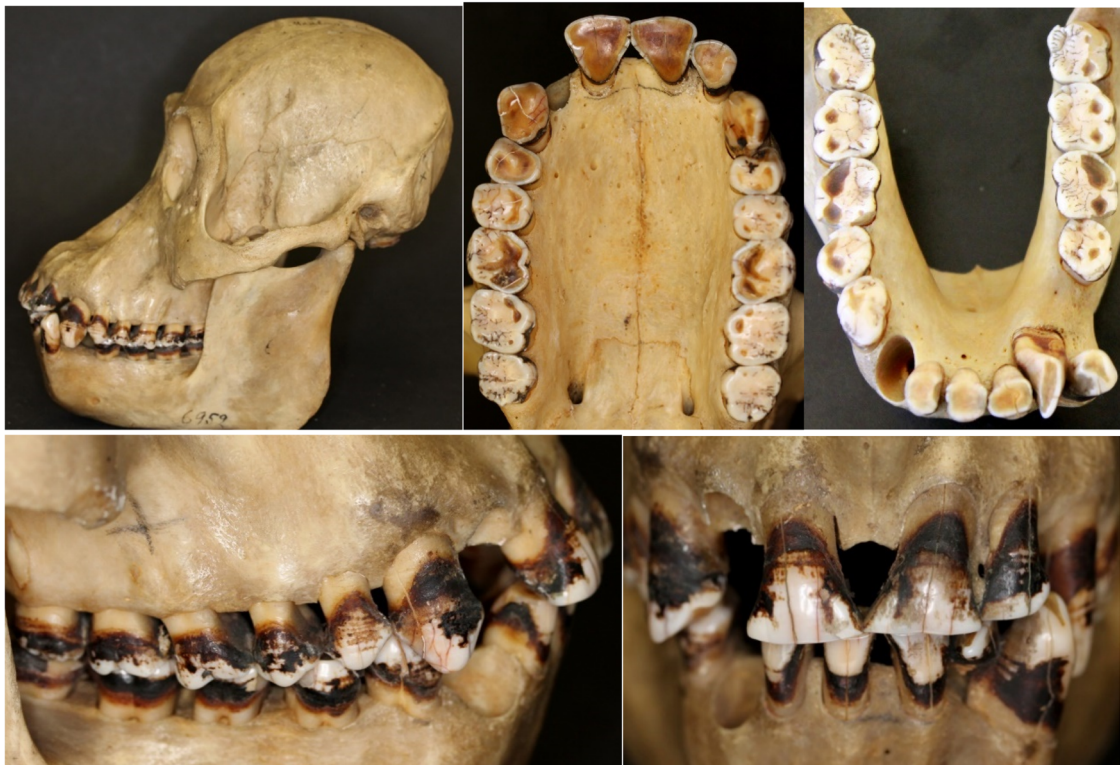Pongo pygmaeus – 6948 - Kelungen/Borneo ♀*Pongo pygmaeus* - 6952 - Moalang/Borneo ♀

FIGURE 3 Female *Pongo pygmaeus*, orang-utan, typical appearance of adults' dentition: pronounced staining and abrasions but no signs of caries or periodontal bone loss. Missing teeth 12 and 43 (6952) were lost *postmortem*.

TABLE 2 Percentage of all examined teeth with incisal/occlusal hard tissue loss until dentin (grade 2 and higher).

Species	Maxillary incisors	Mandibular incisors	Maxillary canini	Mandibular canini	Maxillary premolars	Mandibular premolars	Maxillary molars	Mandibular molars
Gorillas: <i>n</i> = 53	71%	54%	88%	66%	37%	23%	56%	63%
Chimpanzees: <i>n</i> = 63	88%	91%	85%	86%	47%	43%	58%	73%
Orangutans: <i>n</i> = 41	75%	89%	75%	74%	55%	39%	42%	55%

TABLE 3 Number of individuals with other pathologic findings.

Species	Localized periodontitis	Generalized periodontitis	Apical osteolysis	Asymmetric wear of teeth
Gorillas: <i>n</i> = 53	3	0	2	0
Chimpanzees: <i>n</i> = 63	3	3	0	0
Orangutans: <i>n</i> = 41	4	7	3	3

3.2.2 | *Pan troglodytes*

In contrast to gorillas, chimpanzees had more pronounced dental hard tissue defects, with 70% of the teeth having dental hard tissue defects of grade 2 or higher. Among the teeth with dentine exposure, wear of grade 2 predominated, followed by grade 3 at 9%, and grade 4 at only 1%. Approximately 30% of the teeth showed initial defects in the enamel (Table 1).

In chimpanzees, the incisors and canines showed the highest prevalence of wear, with incisors demonstrating marginally greater wear compared with canines. Mandibular molars had more pronounced defects than their corresponding maxillary molars, while premolars had the least extent of wear, aligning with the findings in gorillas (Figure 2, Table 2).

3.2.3 | *Pongo* spp

The degree of wear within the genus *Pongo* spp. was comparable to that found in the genus *Gorilla gorilla*, with 58% of the teeth showing abrasion of grade 2 or higher (Table 1). Wear without dentin involvement was present in 42% of the investigated teeth, while only one of the examined orangutans showed pulp exposure due to abrasion-related injury. The vast majority (88%) had no abrasions exceeding grade 2, indicating an absence of dentine involvement. Notably, specific orangutans exhibited instances of asymmetric loss or fractures of dental hard tissue, suggesting distinct chewing habits involving rigid material such as bark, for example, twigs and branches. Among orangutans (Figure 3), wear was most pronounced in the anterior region, encompassing the incisors and canines—similar to the findings in gorillas. In contrast to the other two investigated species, gorilla and chimpanzee, premolars did not show the least degree of hard tissue loss (Table 2). Comparatively elevated levels of surface wear were evident in both mandibular molars and maxillary premolars, and similarly high levels of wear in maxillary molars and

mandibular premolars. This encompasses both the extent of wear and the prevalence of hard tissue defects.

3.3 | Periodontitis marginalis

Most of the investigated great apes were of good periodontal health (Figures 1–3). However, certain skulls showed severe localized periodontal bone loss (Table 3, Figure 4a,b). In some individuals, attachment loss affected groups of teeth—both molars and premolars—rather than isolated sites (Figure 4c–f).

Overall, generalized periodontitis was absent in gorillas. Among the studied apes, three chimpanzees and seven orangutans exposed generalized bone loss, predominantly at molars and premolars. This was accompanied by exposed furcations of the roots and bowl-shaped defects. Two instances of tooth loss attributed to periodontitis can be inferred, along with typical anterior overturning of posterior teeth (Figure 4).

3.4 | Apical periodontitis (apical osteolysis)

Apical periodontitis/apical osteolysis was identified in five instances (two gorillas, three orangutans, Figure 5). Potential etiological factors for these lesions could encompass trauma, extensive abrasion, fracture of dental hard tissue, or progressive *Periodontitis marginalis profunda*.

4 | DISCUSSION

In line with our predictions, dental examination of great ape skulls revealed pronounced abrasions and discolorations, while notable absence of carious lesions was observed. Certain individuals showed localized or even generalized periodontal bone loss. Additionally,

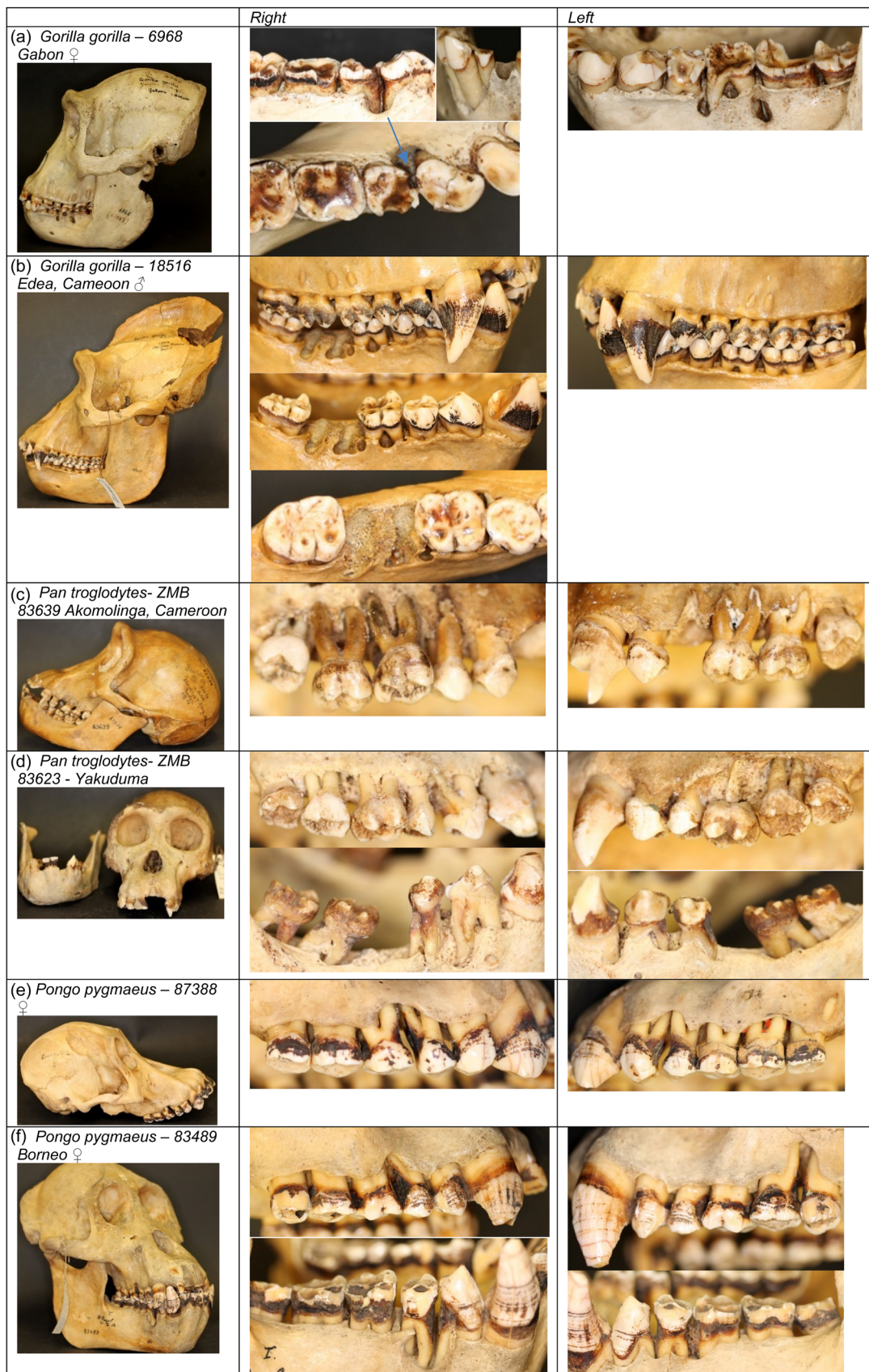


FIGURE 4 (See caption on next page).

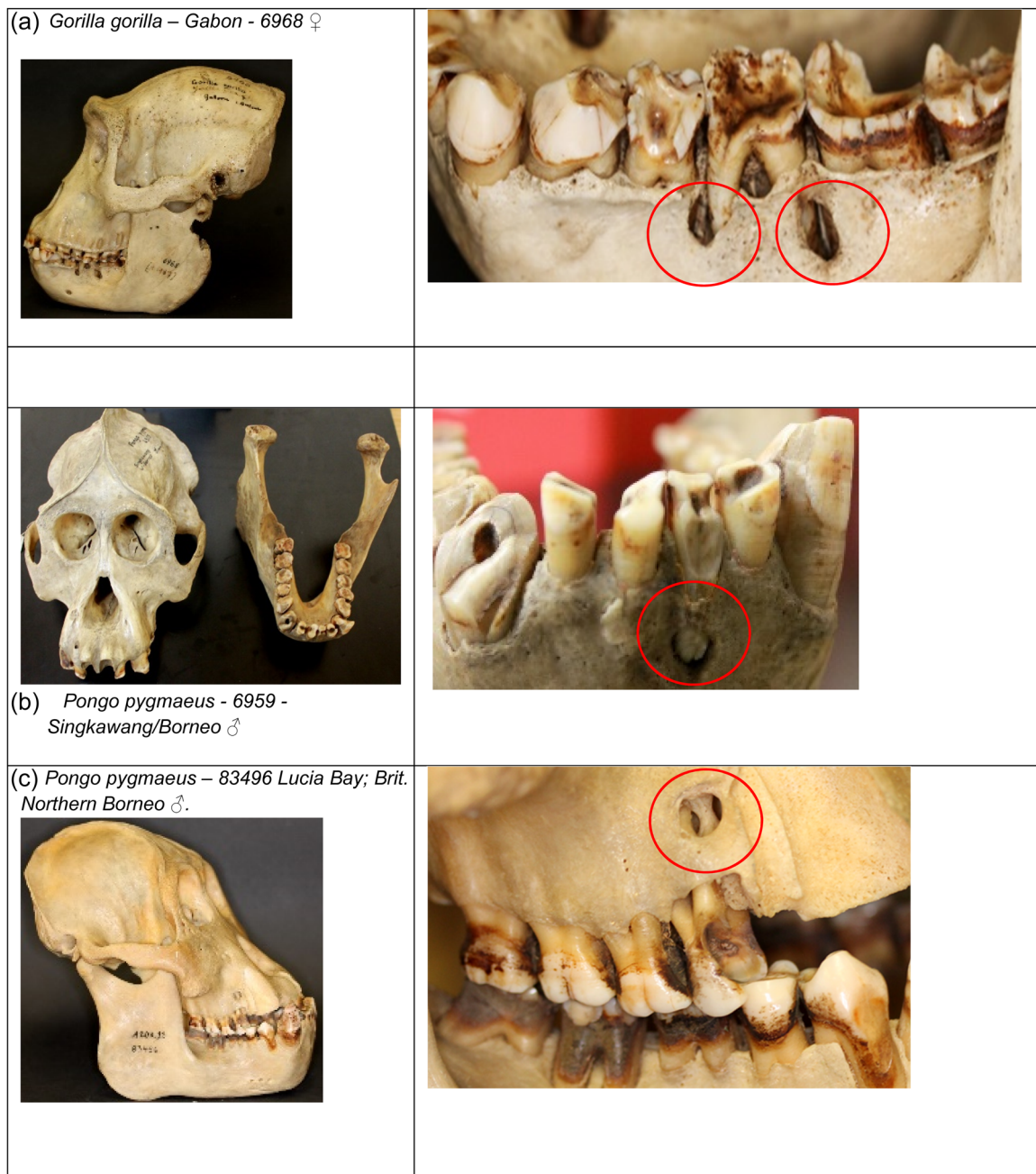


FIGURE 5 Endodontic problems and apical inflammation (red circles) were observed sporadically (a, b, c). Dental traumata, abfraction (a, c), or extreme abrasion with exposure of the pulp chamber (a, b) can be assumed as basic cause.

apical lesions were identified in some teeth among gorillas and orangutans, a manifestation likely attributed to traumatic pulp chamber exposure. Accordingly, the dental assessment indicates the presence of dental health issues among wild-living apes, which is

in line with previous studies (Crovela & Ardito, 1994; Dean et al., 1992; Elgart, 2010; Lowenstine et al., 2016; Schultz, 1935). Furthermore, the observations indicate a prominent influence of diet as a contributing factor.

FIGURE 4 Examples for localized or generalized periodontal bone loss. A small proportion of the examined skulls yielded pronounced periodontal defects; examples are given for all species, buccal perspective of molar teeth. Periodontal defects were rarely observed in *Gorilla gorilla* (a, b), in contrast to *Pan troglodytes* (c, d), and *Pongo pygmaeus* (e, f), there was no individual from the species *Gorilla gorilla* with generalized periodontal bone loss. Loss of teeth due to periodontitis can be postulated for b (47) and d (36, 46); # ZMB 83623 shows the typical anterior overturning of 47/48 and 37/38 following loss of 46 and 36. # 18516 (b) yields somewhat incomplete bony wound healing in region 47 along with bony defects in the furcation of 46.

4.1 | Wear, noncarious loss of dental hard tissue

In our study of wild great ape specimens, we observed considerable tooth wear in all species. It is important to note, however, that these results necessitate cautious interpretation due to limitations posed by the unknown age and dietary habits of the subjects studied. Enamel thickness is a critical factor that impacts tooth wear dynamics. Gorillas, which primarily consume abrasive THV (Doran et al., 2002; Masi et al., 2009; Watts, 1984), have a relatively thin enamel layer characterized by distinct ultrastructural differences that are linked with pronounced wear (Aiello et al., 1991; Elgart, 2010; Welsch, 1967). Chimpanzees have a thinner enamel layer compared with other great apes, and their teeth are smaller than those of gorillas or orangutans (Ungar, 2008). Their enamel is particularly thin in the occlusal fovea (Kono, 2004). However, their diet consists of less abrasive food such as ripe fruits, young leaves, along with mammals, birds, eggs, and insects (McGrew, 1983; Stanford & Nkurunungi, 2003; Tweheyo et al., 2004; Wrangham et al., 1991).

Conversely, orangutans feature thicker enamel, yielding a more gradual progression of abrasion and consequently delayed dentine exposure when compared with other great apes (Dean & Beynon, 1991; Dean et al., 1992; Welsch, 1967). Furthermore, orangutan molars display an arrangement with relatively thin basal and thick occlusal enamel (Kono, 2004).

In addition to enamel thickness, dietary quality is another modulating factor. Western gorillas consume a mixed diet, with only 50% consisting of soft fruits. During periods of food scarcity, gorillas rely mainly on hard, fibrous foods such as leaves and stems, which have a considerable impact on their dental hard tissues (Elizabeth Rogers et al., 1990; McGrew et al., 1988; Remis, 1997; Tutin & Fernandez, 1993; Tutin et al., 1991). Chimpanzees, primarily frugivorous, yield a higher incidence of hard tissue defects in their incisors and canines. Notably, over 85% of the anterior teeth (incisors, canines) exhibit dental hard tissue defects with dentine exposure. This dental health problem aligns with chimpanzees' dietary techniques, which involve using their front teeth to prepare food: fruits and certain plants are peeled; for example, tree bark is peeled off with the incisors and canines (Kilgore, 1989).

4.2 | Caries and biological caries prevention

In the present study, no carious lesions were detected. Analogous patterns of low caries prevalence have been documented in other studies. For instance, only 1.4% of 2890 teeth from chimpanzees in the Senckenberg collection, in Germany, displayed carious lesions, primarily small initial lesions (Fuss et al., 2018).

This is in line with the substantially low prevalence of caries among wild-living apes in comparison to modern humans (Crovella & Ardito, 1994; Dean et al., 1992; Elgart, 2010). The lower prevalence of caries may be attributed to disparities in dietary composition. In contrast to modern human diet, the oral cavity of wild-living apes is less exposed to substantial quantities of low molecular carbohydrates.

Initial carious lesions—as observed in other studies—are likely induced by the seasonal consumption of ripe fruit rich in sugar (Conklin-Brittain et al., 1998; Reynolds et al., 1998; Wrangham et al., 1998). These fruit-derived sugars have the potential to induce initial caries lesions, a notion supported by the identification of the earliest caries lesion in an extinct hominid species, *Dryopithecus carinthiacus*, dating back to the middle Miocene (Fuss et al., 2018).

Caries prevalence might also be modulated by the species-specific eating and mastication habits, particularly “wadging.” During the wadging process, chimpanzees retain chewed fruits in the anterior part of their oral cavity, facilitating the extraction of sugary fluids. This behavior, particularly prominent during the consumption of sugar-rich items such as figs and honeycomb, is likely to contribute to the development of a cariogenic milieu in the interproximal surfaces of their incisors. In turn, wadging may account for the higher prevalence of interproximal lesions observed in incisors of chimpanzees relative to other wild-living primate populations (Towle et al., 2022). In the cited study, general caries rates were 2.6% in gorillas and 9.8% in chimpanzees (Towle et al., 2022).

Another potential factor that could account for the low caries prevalence in apes relative to humans is the heightened chewing activity in apes. Chewing not only stimulates an increase in salivary flow rate but also facilitates certain mechanical cleaning processes. This oral cleaning mechanism may also liberate physiological hydroxyapatite nanoparticles into the saliva, which serve as agents for bacteria aggregation, subsequently being swallowed (Hannig & Hannig, 2010; Kensche et al., 2017).

Moreover, extensive tooth staining (Figures 1–3) indicates the substantial consumption of polyphenolic compounds by great apes. These stains can even mask initial carious lesions and demineralizations. Due to this fact, we might have overlooked initial caries since we were not allowed to remove the stains from the museum specimens. This applies especially for the fissures or the approximal surfaces.

Polyphenols offer local antibacterial, antiadherent, anti-inflammatory, and tanning effects. Additionally, these compounds also strengthen the protective properties of the physiological pellicle layer against acidic agents (Flemming et al., 2021; Hertel et al., 2017; Schestakow et al., 2022). The named findings in humans could be extrapolated to great apes, and potentially help to explain the low caries prevalence also observed in prehistoric gatherers and hunters (Alt et al., 2022; Humphrey et al., 2014; Temple, 2016). Their diet predominantly comprised herbal food such as nuts, seeds, roots and fruit, and a low proportion of proteins from wild animals and fish. These eating habits contributed to infrequent instances of carious teeth (Alt et al., 2022; Gibbons, 2012; Oxilia et al., 2015). Conversely, the advent of agriculture and sedentism led to an increase in carbohydrates intake, paralleled by a modest increase in dental caries in human teeth. This increase was in part compensated by persistent chewing of items, for example, vegetable, nuts, and roots (Alt et al., 2022; Gibbons, 2012; Hannig & Hannig, 2010).

Over the last two millennia, there has been a substantial surge in the consumption of sugars and refined low-molecular-weight

carbohydrates, coupled with a reduction in masticatory intensity. In the absence of proper oral hygiene practice, this shift can lead to an increased caries incidence and prevalence. These findings are consistent with observations from captive great apes over 37 years, some displayed serious caries but minimal dental stains and low level of tooth wear. This may be attributed to their historical consumption of a human-like diet, including sweets, white bread, and considerable amounts of ripe cultivated fruits like bananas. This is in contrast to their current feeding regime, which is primarily based on vegetable and some fruits (Scheels, 2023). In zoo settings, monkeys' diets were changed to include pelleted food and fresh vegetables with a low level of readily digestible carbohydrates, resulting in improved dental health (Plowman, 2013).

4.3 | Endodontic problems

The majority of examined great apes in our study had a robust overall dental health, comparable to that found in ancient human hunter-gatherer populations (Alt et al., 2022). Although our data and other investigations indicate that wild great apes rarely suffer from caries issues, they remain susceptible to other dental issues, such as dental trauma and fractures leading to pulpal and apical inflammation. When pulpal structures are exposed to the abundant oral bacteria due to extensive wear or traumatic fractures, apical lesions can occur which corresponds to the findings in humans (Figure 5).

4.4 | Periodontitis

Periodontal bone loss was observed in some individuals, particularly among orangutans (Figure 4, Table 3). It is plausible that in certain instances, the sustained presence of impacted remnants of branches, barks, or twigs could have induced chronic local inflammation associated with isolated vertical bone loss, indicating localized effects. Nonetheless, instances of generalized periodontal bone loss were identified in single individuals, especially among orangutans but also in chimpanzees. There is already evidence for the occurrence of periodontal diseases in gorillas, chimpanzees, and orangutans (Lovell, 1991), alongside other primates (Gonzalez et al., 2016; Pandruvada et al., 2016; Phillips-Conroy et al., 1993). Case reports described periodontal bone loss in zoo-housed apes (Lowenstine et al., 2016), and generalized periodontal bone loss has been observed in wild-living chimpanzees (Jones & Cave, 1960; Kilgore, 1989). As early as 1973, generalized periodontitis was reported in captive chimpanzees aged 39 and 44 years (Arnold & Baram, 1973).

Some innate or genetic factors (such as activation of osteoclasts by IL-1 or TNF- α) as well as specific bacteria (*Aggregatibacter actinomycetemcomitans*, *Porphyromonas gingivalis*, *Prevotella intermedia*) are associated with severe periodontitis (Das et al., 2023; Sadek et al., 2023). It is noteworthy that genes potentially associated with aggressive periodontitis are present in great apes' genomes (Evanovich et al., 2016). Specific periodontopathogenic bacteria,

such as *Aggregatibacter actinomycetemcomitans*, have been detected in great apes' saliva (Ebersole et al., 2019; Karched et al., 2012), and alterations in neutrophilic granulocytes, typically linked with periodontitis and coronary heart disease, have been investigated in zoo-housed chimpanzees (Raindi et al., 2022). Another study evaluated the bone biology in periodontal structures of *Macaca mulatta* in the context of age and the prevalence of periodontitis. The transcriptome analysis yielded an enhancement of osteoclastic and impaired osteoblastic activity in animals with naturally occurring periodontitis (Pandruvada et al., 2016).

Periodontitis emerges from the interplay between chronic local infection caused by periodontopathogenic bacteria and the organism's inflammatory response, culminating in the loss of periodontal bone (Hajishengallis & Chavakis, 2021). This condition is frequently observed in older individuals across humans (Peres et al., 2019), great apes (Arnold & Baram, 1973), and other primates (Gonzalez et al., 2016; Pandruvada et al., 2016; Phillips-Conroy et al., 1993).

Regarding the dental hard tissue wear in apes with generalized periodontitis, it is conceivable that this disease occurred in an age-dependent manner. However, other allegedly older skulls with extensive wear showed no signs of periodontitis. This is in line with the findings in humans and apes, suggesting that susceptibility to periodontitis varies among individuals (Loos & Van Dyke, 2020). Overall, the interplay between chronic local infections with periodontopathogenic bacteria, organism's inflammatory response, as well as specific innate factors and bacteria, collectively contribute to the age-associated development of periodontitis in humans and apes.

4.5 | Potential correlation of microbiome, lifestyle, and diet

Human saliva has been found to have a higher abundance of caries and periodontitis-relevant bacteria compared with zoo-housed great apes (Boehlke et al., 2020). Furthermore, the salivary microbiome differed between wild chimpanzees (greater abundance of *Bacteroides* and *Fusobacteria*) and humans (Ozga et al., 2019). These and other findings on microbiomes in great apes and humans indicate that lifestyle and diet can induce a shift in the microbiome that facilitates the initiation and progression of chronic dental diseases. For example, a low-carbohydrate diet based on vegetable and avoiding industrial sugar has been shown to reduce gingival inflammation and decreases the load of potentially cariogenic and periodontitis inducing bacterial species in the supragingival oral plaque (Tennert et al., 2020; Woelber et al., 2016; Woelber et al., 2019). These considerations are supported by the skull of a captive orangutan from the same collection, which was not considered in the results. In contrast to wild-livings great apes, there were almost no visible abrasions or stainings, indicating a softer or even human-like diet with low amounts of polyphenols. Accordingly, there was a considerable periodontal bone loss in maxilla (Figure 6).

In summary, the dental findings in wild and zoo-housed great apes confirm and underline previous observations. The evolutionary

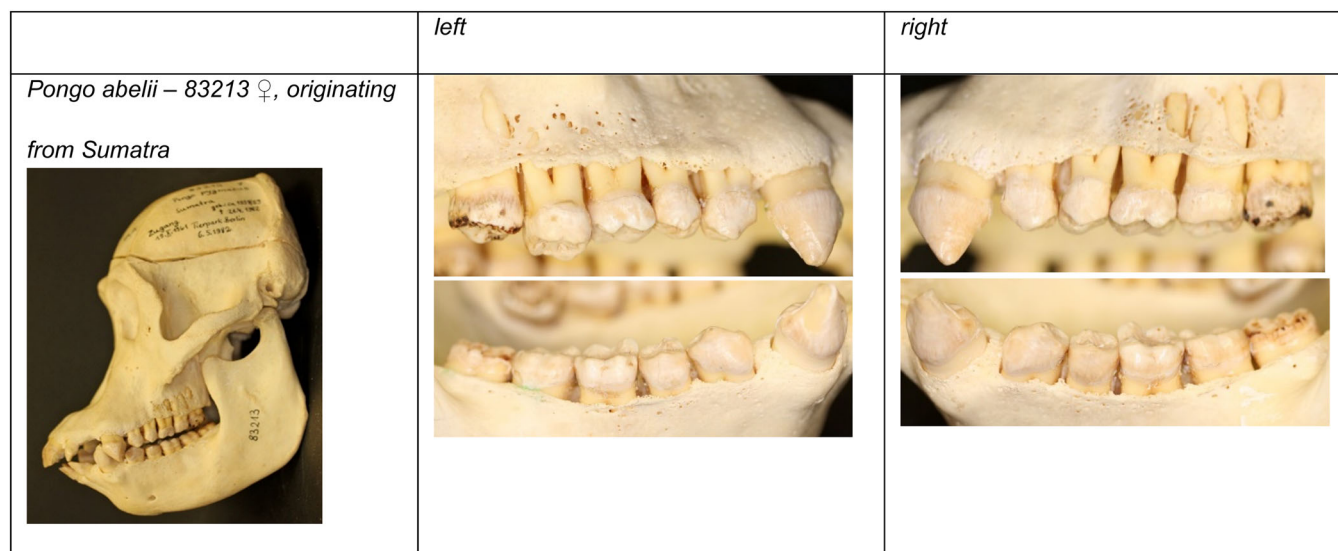


FIGURE 6 Skull of a zoo-housed orangutan, Berlin Zoo, former GDR, born 1958/59, died 21.04.1982, no signs of staining except for third molars in infra-occlusion, nearly no abrasion, generalized periodontitis in the upper jaw with horizontal and vertical bone loss.

and biological perspective considering the interplay of nutrition, foraging microbiome, and oral health that helps to optimize strategies in preventive dentistry.

5 | CONCLUSION

The dental examination of wild-living great apes showed that while they had pronounced abrasions and discolorations, they did not have carious lesions. This could indicate that their diet contained low amounts of cariogenic food but considerable amounts of protective secondary plant components.

However, apical lesions and periodontal bone loss were found in single individuals. Pathologic processes affecting the teeth follow rather similar patterns in great apes and in humans. This can be attributed at least in part to the shared phylogeny modulated by nutrition and the evolutionary adaptation to a species-specific diet.

AUTHOR CONTRIBUTIONS

Acquisition of images and data: Anja Albrecht. *Writing of the manuscript, interpretation of the data:* Verena Behringer. *Writing of the manuscript, interpretation of the data, conception of the study:* Oliver Zierau and Christian Hannig.

ACKNOWLEDGMENTS

The authors would like to express their sincere thanks to PD Dr. Frieder Mayer from the Museum für Naturkunde, Berlin, Germany. Open Access funding enabled and organized by Projekt DEAL.

CONFLICT OF INTEREST STATEMENT

The authors declare no conflict of interest.

DATA AVAILABILITY STATEMENT

All relevant data are included in the manuscript.

ETHICS STATEMENT

No live animals were used in this study, the specimens from wild-living great apes were collected before 1914, before the establishment of guidelines for animal collection. Accordingly, no approval by IACUC or any other institutional committee was required. The research adhered to the American Society of Primatologist's Principles for the Ethical Treatment of Nonhuman Primates.

ORCID

Verena Behringer  <http://orcid.org/0000-0001-6338-7298>

Christian Hannig  <https://orcid.org/0000-0001-8436-5004>

REFERENCES

- Aiello, L. C., Montgomery, C., & Dean, C. (1991). The natural history of deciduous tooth attrition in hominoids. *Journal of Human Evolution*, 21(5), 397–412. [https://doi.org/10.1016/0047-2484\(91\)90114-B](https://doi.org/10.1016/0047-2484(91)90114-B)
- Alt, K. W., Al-Ahmad, A., & Woelber, J. P. (2022). Nutrition and health in human evolution—past to present. *Nutrients*, 14(17), 3594. <https://doi.org/10.3390/nu14173594>
- Ankel-Simons, F. (2007). *Primate anatomy - An introduction* (3rd ed.). Elsevier Academic Press.
- Arnold, L., & Baram, P. (1973). Periodontal disease in chimpanzees. *Journal of Periodontology*, 44(7), 437–442. <https://doi.org/10.1902/jop.1973.44.7.437>
- Boehlke, C., Rupf, S., Tenniswood, M., Chittur, S. V., Hannig, C., & Zierau, O. (2020). Caries and periodontitis associated bacteria are more abundant in human saliva compared to other great apes. *Archives of Oral Biology*, 111, 104648. <https://doi.org/10.1016/j.archoralbio.2020.104648>
- Conklin-Brittain, N. L., Wrangham, R. W., & Hunt, K. D. (1998). Dietary response of chimpanzees and cercopithecines to seasonal variation

- in fruit abundance. *International Journal of Primatology*, 19(6), 971–998. <https://doi.org/10.1023/A:1020370119096>
- Crovella, S., & Ardito, G. (1994). Frequencies of oral pathologies in a sample of 767 non-human primates. *Primates*, 35(2), 225–230. <https://doi.org/10.1007/Bf02382058>
- Cuozzo, F. P., & Sauther, M. L. (2012). What is dental ecology? *American Journal of Physical Anthropology*, 148(2), 163–170. <https://doi.org/10.1002/ajpa.21656>
- Das, V., Vinod, V., Biswas, L., Kumar, A., & Biswas, R. (2023). An update on possible alternative therapeutics for future periodontal disease management. *Journal of Applied Microbiology*, 134(1):lxac039. <https://doi.org/10.1093/jambio/lxac039>
- Dean, M. C., & Beynon, A. D. (1991). Tooth crown heights, tooth wear, sexual dimorphism and jaw growth in hominoids. *Zeitschrift für Morphologie und Anthropologie*, 78(3), 425–440. <https://doi.org/10.1127/zma/78/1991/425>
- Dean, M. C., Jones, M. E., & Pilley, J. R. (1992). The natural history of tooth wear, continuous eruption and periodontal disease in wild shot great apes. *Journal of Human Evolution*, 22, 23–39. [https://doi.org/10.1016/0047-2484\(92\)90027-7](https://doi.org/10.1016/0047-2484(92)90027-7)
- Doran, D. M., McNeilage, A., Greer, D., Bocian, C., Mehlman, P., & Shah, N. (2002). Western lowland gorilla diet and resource availability: New evidence, cross-site comparisons, and reflections on indirect sampling methods. *American Journal of Primatology*, 58(3), 91–116. <https://doi.org/10.1002/ajp.10053>
- Ebersole, J. L., Orraca, L., Kensler, T. B., Gonzalez-Martinez, J., Maldonado, E., & Gonzalez, O. A. (2019). Periodontal disease susceptible matriline in the Cayo Santiago *Macaca mulatta* macaques. *Journal of Periodontal Research*, 54(2), 134–142. <https://doi.org/10.1111/jre.12610>
- Elgart, A. A. (2010). Dental wear, wear rate, and dental disease in the African apes. *American Journal of Primatology*, 72(6), 481–491. <https://doi.org/10.1002/ajp.20797>
- Elizabeth Rogers, M., Maisels, F., Williamson, E. A., Fernandez, M., & Tutin, C. E. G. (1990). Gorilla diet in the Lopé Reserve, Gabon: A nutritional analysis. *Oecologia*, 84(3), 326–339. <https://doi.org/10.1007/BF00329756>
- Evanovich, E., Mendonça-Mattos, P. J. S., & Harada, M. L. (2016). Molecular evolution of the glycosyltransferase 6 gene family in primates. *Biochemistry Research International*, 2016, 1–6. <https://doi.org/10.1155/2016/9051727>
- Flemming, J., Meyer-Probst, C. T., Speer, K., Kölling-Speer, I., Hannig, C., & Hannig, M. (2021). Preventive applications of polyphenols in dentistry—A review. *International Journal of Molecular Sciences*, 22(9), 4892. <https://doi.org/10.3390/ijms22094892>
- Fuss, J., Uhlig, G., & Böhme, M. (2018). Earliest evidence of caries lesion in hominids reveal sugar-rich diet for a Middle Miocene dryopithecine from Europe. *PLoS One*, 13(8), e0203307. <https://doi.org/10.1371/journal.pone.0203307>
- Gerstner, K. F., & Pruetz, J. D. (2022). Wild chimpanzee welfare: A focus on nutrition, foraging and health to inform great ape welfare in the wild and in captivity. *Animals*, 12(23), 3370. <https://doi.org/10.3390/ani12233370>
- Gibbons, A. (2012). An evolutionary theory of dentistry. *Science*, 336(6084), 973–975. <https://doi.org/10.1126/science.336.6084.973>
- Gonzalez, O. A., Orraca, L., Kensler, T. B., Gonzalez-Martinez, J., Maldonado, E., & Ebersole, J. L. (2016). Familial periodontal disease in the Cayo Santiago rhesus macaques. *American Journal of Primatology*, 78(1), 143–151. <https://doi.org/10.1002/ajp.22376>
- Gordon, K. D. (1982). A study of microwear on chimpanzee molars: Implications for dental microwear analysis. *American Journal of Physical Anthropology*, 59(2), 195–215. <https://doi.org/10.1002/ajpa.1330590208>
- Hajishengallis, G., & Chavakis, T. (2021). Local and systemic mechanisms linking periodontal disease and inflammatory comorbidities. *Nature Reviews Immunology*, 21(7), 426–440. <https://doi.org/10.1038/s41577-020-00488-6>
- Hamilton, R. A., & Galdikas, B. M. F. (1994). A preliminary study of food selection by the orangutan in relation to plant quality. *Primates*, 35(3), 255–263. <https://doi.org/10.1007/Bf02382723>
- Hannig, C., & Hannig, M. (2010). Natural enamel wear—A physiological source of hydroxylapatite nanoparticles for biofilm management and tooth repair? *Medical Hypotheses*, 74(4), 670–672. <https://doi.org/10.1016/j.mehy.2009.11.007>
- Hannig, M., & Hannig, C. (2014). The pellicle and erosion. *Monographs in Oral Science*, 25, 206–214. <https://doi.org/10.1159/000360376>
- Hertel, S., Pötschke, S., Basche, S., Delius, J., Hoth-Hannig, W., Hannig, M., & Hannig, C. (2017). Effect of tannic acid on the protective properties of the in situ formed pellicle. *Caries Research*, 51(1), 34–45. <https://doi.org/10.1159/000451036>
- Humphrey, L. T., De Groote, I., Morales, J., Barton, N., Collcutt, S., Bronk Ramsey, C., & Bouzouggar, A. (2014). Earliest evidence for caries and exploitation of starchy plant foods in Pleistocene hunter-gatherers from Morocco. *Proceedings of the National Academy of Sciences*, 111(3), 954–959. <https://doi.org/10.1073/pnas.1318176111>
- Jones, T. S., & Cave, A. J. E. (1960). Diet, longevity and dental disease in the Sierra Leone chimpanzee. *Proceedings of the Zoological Society of London*, 135(1), 147–155. <https://doi.org/10.1111/j.1469-7998.1960.tb05837.x>
- Kaidonis, J. A. (2008). Tooth wear: The view of the anthropologist. *Clinical Oral Investigations*, 12, 21–26. <https://doi.org/10.1007/s00784-007-0154-8>
- Takehashi, S., Baer, P. N., & White, C. L. (1963). Comparative pathology of periodontal disease. *Oral Surgery, Oral Medicine, Oral Pathology*, 16, 397–406. [https://doi.org/10.1016/0030-4220\(63\)90166-x](https://doi.org/10.1016/0030-4220(63)90166-x)
- Kalluri, S. (2021). Evaluation of oral pathologies in *Pan paniscus* using CT. (*Master of Science*). Texas A&M University.
- Karched, M., Furgang, D., Sawalha, N., & Fine, D. H. (2012). Rapid identification of oral isolates of *Aggregatibacter actinomycetemcomitans* obtained from humans and primates by an ultrafast super convection based polymerase chain reaction. *Journal of Microbiological Methods*, 89(1), 71–75. <https://doi.org/10.1016/j.mimet.2012.01.016>
- Kensche, A., Holder, C., Basche, S., Tahan, N., Hannig, C., & Hannig, M. (2017). Efficacy of a mouthrinse based on hydroxyapatite to reduce initial bacterial colonisation in situ. *Archives of Oral Biology*, 80, 18–26. <https://doi.org/10.1016/j.archoralbio.2017.03.013>
- Kilgore, L. (1989). Dental pathologies in ten free-ranging chimpanzees from Gombe National Park, Tanzania. *American Journal of Physical Anthropology*, 80(2), 219–227. <https://doi.org/10.1002/ajpa.1330800210>
- Knott, C. D. (1998). Changes in orangutan caloric intake, energy balance, and ketones in response to fluctuating fruit availability. *International Journal of Primatology*, 19(6), 1061–1079. <https://doi.org/10.1023/A:1020330404983>
- Kono, R. T. (2004). Molar enamel thickness and distribution patterns in extant great apes and humans: New insights based on a 3-dimensional whole crown perspective. *Anthropological Science*, 112(2), 121–146. <https://doi.org/10.1537/ase.03106>
- Kuhlwillm, M., de Manuel, M., Nater, A., Greminger, M. P., Krutzen, M., & Marques-Bonet, T. (2016). Evolution and demography of the great apes. *Current Opinion in Genetics & Development*, 41, 124–129. <https://doi.org/10.1016/j.gde.2016.09.005>
- Legge, S. S. (2012). Dentoalveolar abscess variation among three groups of chimpanzees (*Pan troglodytes schweinfurthii*, *Pan troglodytes troglodytes*, and *Pan paniscus*). *International Journal of*

- Paleopathology*, 2(1), 1–9. <https://doi.org/10.1016/j.jipp.2012.06.002>
- Loos, B. G., & Van Dyke, T. E. (2020). The role of inflammation and genetics in periodontal disease. *Periodontology* 2000, 83(1), 26–39. <https://doi.org/10.1111/prd.12297>
- Lovell, N. C. (1991). An evolutionary framework for assessing illness and injury in nonhuman primates. *American Journal of Physical Anthropology*, 34, 117–155. <https://doi.org/10.1002/ajpa.1330340608>
- Lowenstine, L. J., McManamon, R., & Terio, K. A. (2016). Comparative pathology of aging great apes: Bonobos, chimpanzees, gorillas, and orangutans. *Veterinary Pathology*, 53(2), 250–276. <https://doi.org/10.1177/0300985815612154>
- Lukacs, J. R. (1999). Enamel hypoplasia in deciduous teeth of great apes: Do differences in defect prevalence imply differential levels of physiological stress? *American Journal of Physical Anthropology*, 110(3), 351–363. [https://doi.org/10.1002/\(Sici\)1096-8644\(199911\)110:3%3C351::Aid-Ajpa7%3E3.0.Co;2-2](https://doi.org/10.1002/(Sici)1096-8644(199911)110:3%3C351::Aid-Ajpa7%3E3.0.Co;2-2)
- Lussi, A., & Ganss, C. (2014). *Erosive tooth wear: From diagnosis to therapy, 2nd, revised and extended edition of dental erosion – From diagnosis to therapy* (Vol. 25, 2nd ed.).
- Mackinnon, J. (1974). The behaviour and ecology of wild orang-utans (*Pongo pygmaeus*). *Animal Behaviour*, 22(1), 3–74. [https://doi.org/10.1016/S0003-3472\(74\)80054-0](https://doi.org/10.1016/S0003-3472(74)80054-0)
- Masi, S., Cipolletta, C., & Robbins, M. M. (2009). Western lowland gorillas (*Gorilla gorilla gorilla*) change their activity patterns in response to frugivory. *American Journal of Primatology*, 71(2), 91–100. <https://doi.org/10.1002/ajp.20629>
- McGrew, W. C. (1983). Animal foods in the diets of wild chimpanzees (*Pan troglodytes*): Why cross-cultural variation? *Journal of Ethology*, 1, 46–61. <https://doi.org/10.1007/BF02347830>
- McGrew, W. C., Baldwin, P. J., & Tutin, C. E. G. (1988). Diet of wild chimpanzees (*Pan troglodytes verus*) at Mt. Assirik, Senegal: I. Composition. *American Journal of Primatology*, 16(3), 213–226. <https://doi.org/10.1002/ajp.1350160304>
- Molnar, S., & Molnar, I. (1985). Observations of dental diseases among prehistoric populations of Hungary. *American Journal of Physical Anthropology*, 67(1), 51–63. <https://doi.org/10.1002/ajpa.1330670107>
- Münster, A., Knipper, C., Oelze, V. M., Nicklisch, N., Stecher, M., Schlenker, B., Ganslmeier, R., Fragata, M., Friederich, S., Dresely, V., Hubensack, V., Brandt, G., Döhle, H. J., Vach, W., Schwarz, R., Metzner-Nebelsick, C., Meller, H., & Alt, K. W. (2018). 4000 years of human dietary evolution in central Germany, from the first farmers to the first elites. *PLoS One*, 13(3), e0194862. <https://doi.org/10.1371/journal.pone.0194862>
- Ormond, C., Douglas, G., & Pitts, N. (2010). The use of the International Caries Detection and Assessment System (ICDAS) in a National Health Service general dental practice as part of an oral health assessment. *Primary Dental Care*, 17(4), 153–160. <https://doi.org/10.1308/135576110792936177>
- Oxilia, G., Peresani, M., Romandini, M., Matteucci, C., Spiteri, C. D., Henry, A. G., Schulz, D., Archer, W., Crezzini, J., Boschin, F., Boscato, P., Jaouen, K., Dogandzic, T., Broglio, A., Moggi-Cecchi, J., Fiorenza, L., Hublin, J. J., Kullmer, O., & Benazzi, S. (2015). Earliest evidence of dental caries manipulation in the Late Upper Palaeolithic. *Scientific Reports*, 5, 12150. <https://doi.org/10.1038/srep12150>
- Ozga, A. T., Gilby, I., Nockerts, R. S., Wilson, M. L., Pusey, A., & Stone, A. C. (2019). Oral microbiome diversity in chimpanzees from Gombe National Park. *Scientific Reports*, 9(1), 17354. <https://doi.org/10.1038/s41598-019-53802-1>
- Pandruvada, S. N., Gonzalez, O. A., Kirakodu, S., Gudhimella, S., Stromberg, A. J., Ebersole, J. L., Orraca, L., Gonzalez-Martinez, J., Novak, M. J., & Huja, S. S. (2016). Bone biology-related gingival transcriptome in ageing and periodontitis in non-human primates. *Journal of Clinical Periodontology*, 43(5), 408–417. <https://doi.org/10.1111/jcpe.12528>
- Peres, M. A., Macpherson, L. M. D., Weyant, R. J., Daly, B., Venturelli, R., Mathur, M. R., Listl, S., Celeste, R. K., Guarnizo-Herreño, C. C., Kearns, C., Benzan, H., Allison, P., & Watt, R. G. (2019). Oral diseases: A global public health challenge. *The Lancet*, 394(10194), 249–260. [https://doi.org/10.1016/S0140-6736\(19\)31146-8](https://doi.org/10.1016/S0140-6736(19)31146-8)
- Phillips-Conroy, J. E., Hildebolt, C. F., Altmann, J., Jolly, C. J., & Muruthi, P. (1993). Periodontal health in free-ranging baboons of Ethiopia and Kenya. *American Journal of Physical Anthropology*, 90(3), 359–371. <https://doi.org/10.1002/ajpa.1330900310>
- Plowman, A. (2013). Diet review and change for monkeys at Paignton Zoo Environmental Park. *Journal of Zoo and Aquarium Research*, 1(2), 73–77.
- Raindi, D., Rees, J., Hirschfeld, J., Wright, H., Dobbs, P., Moittié, S., White, K., Stahl, W., Martin, M., Redrobe, S., Hughes, F., Liptovszky, M., Baiker, K., & Grant, M. (2022). Periodontal health, neutrophil activity and cardiovascular health in captive chimpanzees. *Archives of Oral Biology*, 134, 105342. <https://doi.org/10.1016/j.archoralbio.2021.105342>
- Remis, M. J. (1997). Western lowland gorillas (*Gorilla gorilla gorilla*) as seasonal frugivores: Use of variable resources. *American Journal of Primatology*, 43(2), 87–109. [https://doi.org/10.1002/\(Sici\)1098-2345\(1997\)43:2%3C87::Aid-Ajp1%3E3.0.Co;2-T](https://doi.org/10.1002/(Sici)1098-2345(1997)43:2%3C87::Aid-Ajp1%3E3.0.Co;2-T)
- Reynolds, V., Plumpré, A. J., Greenham, J., & Harborne, J. (1998). Condensed tannins and sugars in the diet of chimpanzees (*Pan troglodytes schweinfurthii*) in the budongo forest, Uganda. *Oecologia*, 115(3), 331–336. <https://doi.org/10.1007/s004420050524>
- Sadek, K., El Moshy, S., Radwan, I., Rady, D., Abbass, M., El-Rashidy, A., Dörfer, C., & Fawzy El-Sayed, K. (2023). Molecular basis beyond interrelated bone resorption/regeneration in periodontal diseases: A concise review. *International Journal of Molecular Sciences*, 24(5), 4599. <https://doi.org/10.3390/ijms24054599>
- Scheels, J. L. (2023). A retrospective review of dental care and related husbandry of captive great apes over 37 years (1982–2019) at Milwaukee County Zoo. *Journal of Veterinary Dentistry*, 40(3), 243–249. <https://doi.org/10.1177/08987564231151843>
- Schestakow, A., Nekrashevych, Y., Hoth-Hannig, W., & Hannig, M. (2022). Influence of periodic polyphenol treatment on the anti-erosive potential of the acquired enamel pellicle—A qualitative exploratory study. *Journal of Dentistry*, 124, 104236. <https://doi.org/10.1016/j.jdent.2022.104236>
- Schultz, A. H. (1935). Eruption and decay of the permanent teeth in primates. *American Journal of Physical Anthropology*, 19(4), 489–581. <https://doi.org/10.1002/ajpa.1330190417>
- Stanford, C. B., & Nkurunungi, J. B. (2003). Behavioral ecology of sympatric chimpanzees and gorillas in Bwindi Impenetrable National Park, Uganda: Diet. *International Journal of Primatology*, 24(4), 901–918. <https://doi.org/10.1023/A:1024689008159>
- Stoner, K. E. (1995). Dental pathology in *Pongo satyrus borneensis*. *American Journal of Physical Anthropology*, 98(3), 307–321. <https://doi.org/10.1002/ajpa.1330980305>
- Temple, D. H. (2016). Caries: The ancient scourge. In J. D. Irish & G. R. Scott (Eds.), *Companion to Dental Anthropology* (pp. 433–449). Wiley.
- Tennert, C., Reinmuth, A. C., Bremer, K., Al-Ahmad, A., Karygianni, L., Hellwig, E., Vach, K., Ratka-Krüger, P., Wittmer, A., & Woelber, J. P. (2020). An oral health optimized diet reduces the load of potential cariogenic and periodontal bacterial species in the supragingival oral plaque: A randomized controlled pilot study. *MicrobiologyOpen*, 9(8), e1056. <https://doi.org/10.1002/mbo3.1056>
- Towle, I., Irish, J. D., & De Groote, I. (2017). Dental pathology, wear, and developmental defects in South African hominins. *American Journal of Physical Anthropology*, 162, 384.

- Towle, I., Irish, J. D., Sabbi, K. H., & Loch, C. (2022). Dental caries in wild primates: Interproximal cavities on anterior teeth. *American Journal of Primatology*, 84(1), e23349. <https://doi.org/10.1002/ajp.23349>
- Tutin, C. E. G., & Fernandez, M. (1993). Composition of the diet of chimpanzees and comparisons with that of sympatric lowland gorillas in the Lopé reserve, Gabon. *American Journal of Primatology*, 30(3), 195–211. <https://doi.org/10.1002/ajp.1350300305>
- Tutin, C. E. G., Fernandez, M., Rogers, M. E., Williamson, E. A., & McGrew, W. C. (1991). Foraging profiles of sympatric lowland gorillas and chimpanzees in the Lopé Reserve, Gabon. *Philosophical Transactions of the Royal Society of London. Series B: Biological Sciences*, 334(1270), 179–186. <https://doi.org/10.1098/rstb.1991.0107>
- Tweheyo, M., Lye, K. A., & Weladji, R. B. (2004). Chimpanzee diet and habitat selection in the Budongo Forest Reserve, Uganda. *Forest Ecology and Management*, 188(1–3), 267–278. <https://doi.org/10.1016/j.foreco.2003.07.028>
- Ungar, P. (2008). Strong teeth, strong seeds. *Nature*, 452(7188), 703–704. <https://doi.org/10.1038/452703a>
- Uwimbabazi, M., Rothman, J. M., Basuta, G. I., Machanda, Z. P., Conklin-Brittain, N. L., & Wrangham, R. W. (2019). Influence of fruit availability on macronutrient and energy intake by female chimpanzees. *African Journal of Ecology*, 57(4), 454–465. <https://doi.org/10.1111/aje.12636>
- Watts, D. P. (1984). Composition and variability of mountain gorilla diets in the central Virungas. *American Journal of Primatology*, 7(4), 323–356. <https://doi.org/10.1002/ajp.1350070403>
- Welsch, U. (1967). Tooth wear in living Pongids. *Journal of Dental Research*, 46(5), 989–992. <https://doi.org/10.1177/00220345670460056201>
- Woelber, J. P., Bremer, K., Vach, K., König, D., Hellwig, E., Ratka-Krüger, P., Al-Ahmad, A., & Tennert, C. (2016). An oral health optimized diet can reduce gingival and periodontal inflammation in humans—A randomized controlled pilot study. *BMC Oral Health*, 17(1), 28. <https://doi.org/10.1186/s12903-016-0257-1>
- Woelber, J. P., Gärtner, M., Breuninger, L., Anderson, A., König, D., Hellwig, E., Al-Ahmad, A., Vach, K., Dötsch, A., Ratka-Krüger, P., & Tennert, C. (2019). The influence of an anti-inflammatory diet on gingivitis. A randomized controlled trial. *Journal of Clinical Periodontology*, 46(4), 481–490. <https://doi.org/10.1111/jcpe.13094>
- Wrangham, R. W., Conklin, N. L., Chapman, C. A., & Hunt, K. D. (1991). The significance of fibrous foods for Kibale Forest chimpanzees. *Philosophical Transactions of the Royal Society of London. Series B: Biological Sciences*, 334(1270), 171–178. <https://doi.org/10.1098/rstb.1991.0106>
- Wrangham, R. W., Conklin-Brittain, N. L., & Hunt, K. D. (1998). Dietary response of chimpanzees and cercopithecines to seasonal variation in fruit abundance. I. Antifeedants. *International Journal of Primatology*, 19(6), 949–970. <https://doi.org/10.1023/A:1020318102257>

How to cite this article: Albrecht, A., Behringer, V., Zierau, O., & Hannig, C. (2023). Dental findings in wild great apes from macerated skull analysis. *American Journal of Primatology*, e23581. <https://doi.org/10.1002/ajp.23581>